

Tapirus terrestris. By Miguel Padilla and Robert C. Dowler

Published 2 December 1994 by The American Society of Mammalogists

***Tapirus terrestris* (Linnaeus, 1758)**

Brazilian Tapir

- Hippopotamus terrestris* Linnaeus, 1758:74. Type locality "Brazilia" restricted to Pernambuco, Brazil by Thomas (1911).
Hydrochaerus tapir Erxleben, 1777:191. Type locality restricted to Surinam by Hershkovitz (1954).
Tapir suillus Blumenbach, 1779:129. Type locality restricted to Surinam by Hershkovitz (1954).
Tapir (Anta) Zimmermann, 1780:154. Type locality restricted to Pernambuco, Brazil by Hershkovitz (1954).
Tapir americanus Gmelin, 1788:216. Type locality restricted to Surinam by Hershkovitz (1954).
Tapirus rufus Fischer, 1814:292. Type locality Guiana, probably French Guiana (Hershkovitz, 1954).
Tapir maypuri Roulin, 1829:45. Type locality restricted to Guianas by Hershkovitz (1954).
Tapirus laurillardi Gray, 1867:881. Type locality "South America," restricted to Pernambuco, Brazil, by Hershkovitz (1954).
Tapirus terrestris Gray, 1867:879; first use of name combination.
Tapirus aenigmaticus Gray, 1872:490. Type locality "Sunia," Cordillera Oriental, Ecuador, but according to Hershkovitz (1954:481) "almost certainly from Macas, eastern Ecuador."
Tapirus ecuadorensis Gray, 1872:492. Type locality "Macas, eastern Ecuador."
Tapirus sabatyra Liais, 1872:397, renaming of *T. terrestris* Linnaeus.
Tapirus tapirus Merriam, 1895:376, renaming of *T. terrestris* Linnaeus.
Tapirus spegazzinii Ameghino, 1909:31. Type locality "Río Pescado, Departamento de Orán, Salta, Argentina."
Tapirus anulipes Hermann, 1924:167. Type locality "Cuyabá, Mato Grosso, Brazil."

CONTEXT AND CONTENT. Order Perissodactyla, Suborder Ceratomorpha, Superfamily Tapiroidea, Family Tapiridae, Genus *Tapirus* and Subgenus *Tapirus*. There are four subspecies (Cabrera, 1961):

- T. t. aenigmaticus* Gray, 1872:490, see above (*americanus* Tschudi, *leucogenys* Gray, *ecuadorensis* Gray, *peruvianus* Gray, and *roulini* Selater are synonyms).
T. t. colombianus Hershkovitz, 1954:486. Type locality "El Salado, eastern slope of Sierra Nevada de Santa Marta, on road between Valencia and Pueblo Bello, Department of Magdalena, Colombia; altitude, 430 meters."
T. t. spegazzinii Ameghino, 1909:31, see above (*anulipes* Hermann is a synonym).
T. t. terrestris (Linnaeus, 1758:74), see above (*americanus* Gmelin, *anta* Zimmerman, *brasiliensis* Liais, *guianae* J. A. Allen, *laurillardi* Gray, *maypuri* Roulin, *mexicanae* Lydekker, *rufus* G. Fischer, *sabatyra* Liais, *suillus* Blumenbach, *tapir* Erxleben, and *tapirus* Merriam are synonyms).

DIAGNOSIS. *Tapirus terrestris* is larger than *T. pinchaque* but smaller than *T. indicus* and *T. bairdii*, with *T. bairdii* about 16% longer and 50% heavier (Hershkovitz, 1954). *T. terrestris* and *T. pinchaque* possess one sagittal crest whereas other tapirs have double crests. The crest of *T. pinchaque* is smaller, however, and divides into a triangular table above the occiput. The hair of *T. terrestris* is much shorter than that of *T. pinchaque*. Only *T. terrestris* and *T. bairdii* have manes (Earle, 1889). The Brazilian tapir is generally uniform brown in color in contrast to the distinct black and white pattern of *T. indicus*. *T. terrestris* also differs from *T. indicus* in absence or less development of well-marked valvulae conniventes in the small intestine, presence of a moderator band in

the heart, having a more elongated cecum sacculated by four bands (Beddard, 1889), and having a reduced and functionless lateral toe on the pes (Earle, 1889).

GENERAL CHARACTERS. An adult female *T. terrestris* and calf are shown in Fig. 1. The head of the Brazilian tapir has a convex appearance due to the prominent sagittal crest. A short, narrow mane runs from the base of the muzzle to the middle of the back. The upper lip is long and prehensile, as is the proboscis. The legs are short and the forelegs have bald callosities. The manus is tetradactyl and the pes is tridactyl, both having hooves with thick callous toci. The prepuce is short and wide and does not reach the middle of the abdomen (Turner, 1850). A single pair of mammary glands is located in the inguinal region (Kuehn, 1986).

Adults generally are between 150 and 250 kg in mass, with shoulder height ranging from 77 to 108 cm; total length of body ranges to 221 cm for females and 204 cm for males. Length of tail is about 8 cm and length of ears is 12 cm. The hind foot of two adults averaged 343 mm, and an adult with a mass of 250 kg had a thoracic circumference of 1215 mm (Hershkovitz, 1954). Mallinson (1969) noted that females seem to be longer on average than males, but Simpson (1945) found few osteological or dental differences between sexes.

The sagittal crest is a prominent feature of the skull of *T. terrestris* (Fig. 2). Means of selected cranial measurements of *T. t. terrestris* (in mm; *n* in parentheses) are: condylobasal length, 368.7 (7); zygomatic breadth, 174.9 (9); interorbital constriction, 84.9 (9); breadth of braincase, 96.6 (9); greatest length of nasals, 92.4 (8); length of mandible, 287.3 (8) (Husson, 1978).

The skin of *T. terrestris* is thickest at the nape (Hershkovitz, 1954), delicate, and often covered by scars, scratches, and bruises; beneath the epidermis is a fibrous tissue layer (Fradrich and Thienius, 1972). The color of adult *T. t. terrestris* is blackish brown dorsally with the ears edged in white; the chest, venter, and limbs are dark brown; the mane black; the cheeks grizzled brown and gray; the throat gray; the neck brown; and the chin blackish brown. Other subspecies are paler (Hershkovitz, 1954).

DISTRIBUTION. The geographic range of *T. terrestris* (Fig. 3) includes areas from Rio Grande do Sul, Brazil, the Chaco of Argentina, Paraguay and Bolivia, northward through the Amazonian region of Brazil, Bolivia, Peru, Ecuador, Colombia, French Guiana, Surinam, and in Venezuela westward across the Sierra de Perira of



FIG. 1. Female *Tapirus terrestris* with juvenile. Photograph provided by the New York Zoological Society.

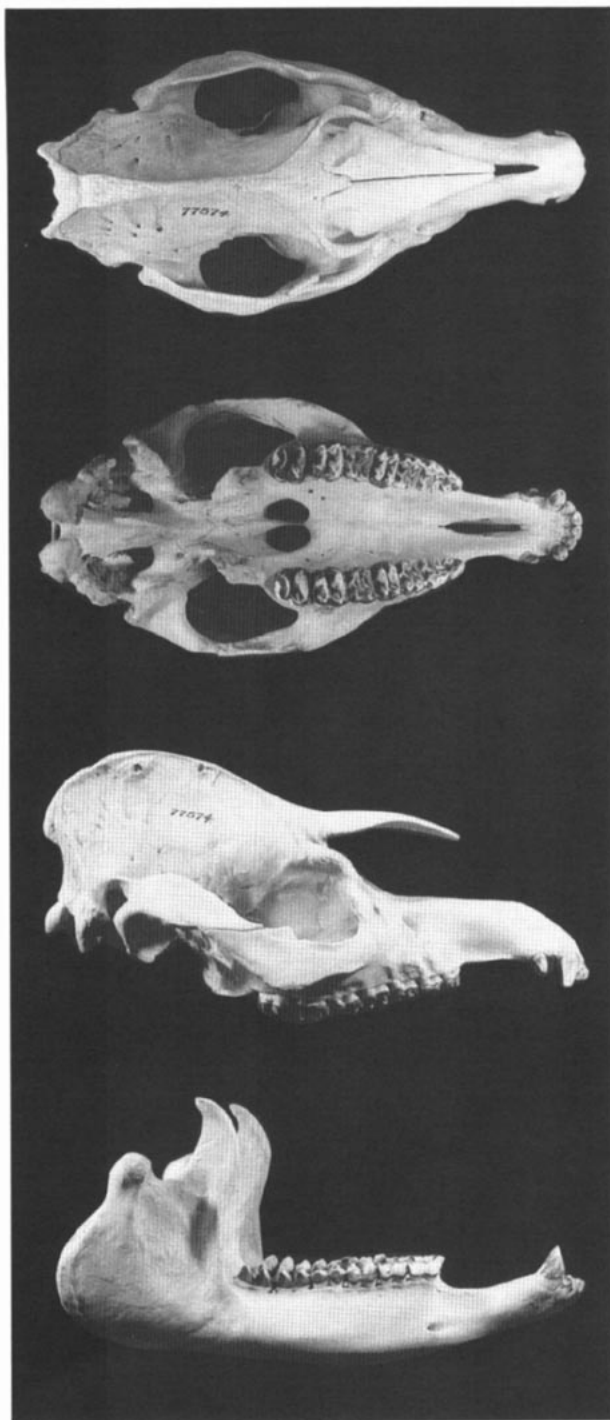


FIG. 2. Dorsal, ventral, and lateral views of cranium, and lateral view of mandible of male *Tapirus terrestris* (AMNH 77574). Condylobasal length of cranium is 335 mm.

the Cordillero Oriental into northern Colombia (Hershkovitz, 1954). *T. t. aenigmaticus* is found in southeastern Colombia, eastern Ecuador and northeastern Peru (Cabrera, 1961). *T. t. spegazzinii* occurs in southeastern Brazil, Mato Grosso, eastern Bolivia, Paraguay, and northern Argentina to eastern Salta and the extreme northeast of Tucumán. *T. t. terrestris* occurs in Surinam, French Guiana, Brazil, and Venezuela, southward to Misiones, Argentina. *T. t. colombianus* historically was found in the tropical zones of northern Colombia in the departments of Magdalena, Bolivar, Atlantico Cordoba, and northwestern Antioquia, as far west as the Río Atrata, as far north as the Río Rancheria in La Guajira, and in the

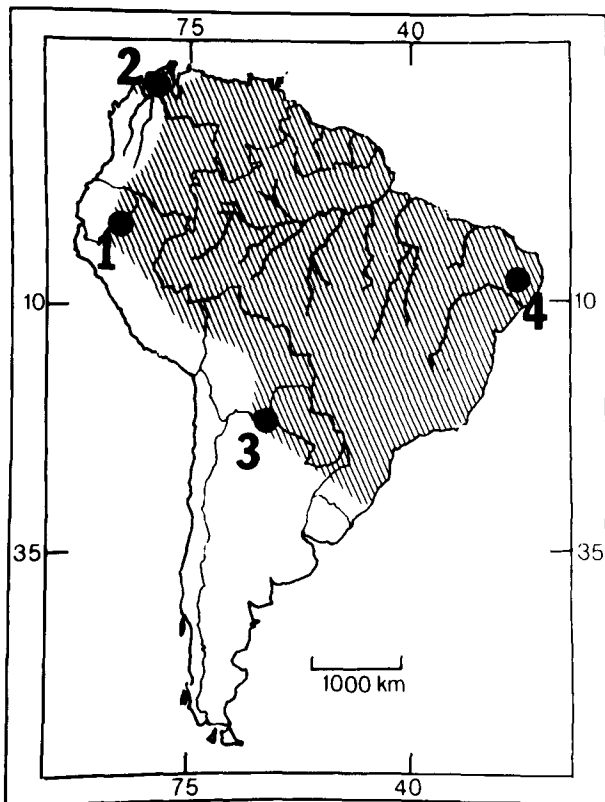


FIG. 3. Distribution of *Tapirus terrestris*. Numbers represent type localities of subspecies as follows: 1, *T. t. aenigmaticus*; 2, *T. t. colombianus*; 3, *T. t. spegazzinii*; 4, *T. t. terrestris*.

Lake Maracaibo region of Venezuela (Cabrera, 1961; Hershkovitz, 1954).

FOSSIL RECORD. The earliest known record of *Tapirus* in South America is from the Uquian land mammal age (2.5–1.5 million years before present (MYBP)) in Argentina. *Tapirus* is also known from the Ensenadan land mammal age (1.5–0.5 MYBP) in Bolivia and Peru (Webb, 1985). In North America, the fossil record for *Tapirus* extends from the late Miocene through the Pleistocene. Fossil remains of *T. terrestris* from the Pleistocene were found in the upper Jurua River region, State of Acre, Brazil (Simpson and Paula Couto, 1981), from Jacu Pirango in São Paulo, Brazil (Paula Couto, 1980), and Jaupaci, Brazil (Moreira, 1973).

FORM AND FUNCTION. The dental formula is $i\ 3/3, c\ 1/1, p\ 4/3, m\ 3/3$, total 42. The canines have little cementum compared with those of other mammals; the cementum is arranged in minute columns with lacunae and canaliculi traversing it (Tomes, 1851). The I3 is large and heavy, separated from the canine by a diastema about the same length as the alveolus of the I3. The lower incisors decrease in size from $i1$ to $i3$ (Husson, 1978). The upper canines are reduced, and caniniform lateral incisors oppose the well-developed lower canines; the posterior three premolars are molariform; the upper molars have a pair of simple cross lophs and a short ectoloph (Romer, 1966). The P1 usually contains a continuous ectoloph, extending from the parastyle to the metacone, and a paracone merged into a weak labial ridge, but a P1 with a large, isolated paracone and no protocone or ectoloph was described by Hooijer (1961).

Prelacteal dentition, in the form of a single functional premilk premolar, was found in an 8-day-old calf (Ameghino, 1911). In addition to the deciduous dentition, the first molar is also present in newborn tapirs (Schinz, 1937). Measurements of permanent and deciduous teeth are available in Koenigswald (1930) and Simpson (1945).

The proboscis has two strong round levatores muscles arising from the ossa nasi. The depressores arise from the intermaxillary bones and fasciculi are present (Owen, 1830). The lateral cartilages of the proboscis arise from the septum beneath the ossa nasi and

end in a notch on each side of the base of the nasal bones. There are no alar cartilages and the rest of the proboscis is soft. The skull has anterior nasal openings that are enlarged and recessed (Turner, 1850). A weakly developed flange of the maxilla is present in some *T. terrestris*, where it is found medial to the posterior process of the premaxilla (Ray and Sanders, 1984).

The opening of the auditory meatus is variable, being widely open ventrally in some skulls; in others, a mastoid process severely constricts the opening (Hatcher, 1896). The sagittal crest develops unusually early in life (Ray and Sanders, 1984). The larynx has a weakly developed basihyal and no strong epihyal process (Turner, 1850). The os hyoides articulates with the base of the styloid processes (Owen, 1830).

The vertebral formula for *Tapirus terrestris* is 7 C, 26 T, 4 L, 6 S, 5 Ca, total 48. There are five sternebrae (Schinz, 1937). The atlas and axis were described by Kladetzky (1956). Details of the skeletal structure of the forelimbs and hindlimbs were reported by Earle (1889), Kathariner (1914), and Klaitz (1972). A morphofunctional analysis of locomotion in the Brazilian tapir was given by Gambaryan (1964).

The muscles of the pes are more specialized than those of the manus. Each digit has three lumbricales pedis and all three toes have two flexores breves profundi pedis (interossei). The second and fourth toes have a contrahentes digitorum pedis (Campbell, 1945).

The muscular anatomy of the buccopharyngeal and cervical regions was described by Lechner (1932) and the auricular muscles by Donat (1980). In the shoulder, the cephalohumeralis arises from the mastoid of the skull and fuses with the pectoralis superficialis, and by its origin, represents the cleidomastoid and cleidotrapezius of other mammals. The levator scapulae ventralis has fused with the acromiodeltoid to form the humerotransversalis; a brachioradialis is present. The extensor carpi ulnaris has lost its extensor action. Other muscles of the limbs were described by Campbell (1936) and Turner (1850).

The blood of a captive animal had an average erythrocyte count of 12,510,000/mm³ of blood. The leucocyte count was 9,200 (Evarestova, 1946). The hemoglobin of the Brazilian tapir consists of two chains (alpha I and alpha II), and beta major and minor components. Whereas the alpha chains differ only at one position, the beta chains are heterogeneous (Mazur and Braunitzer, 1984).

The circulatory anatomy of the cranial region was described by Frackowiak and Godynicki (1992) and that of the buccal, pharyngeal and cervical regions was described by Lechner (1932). The spleen measures about 45 by 10 cm and the heart is 17.5 cm long and 15 cm wide at the base (Owen, 1830). The cardiac moderator band has three limbs attached to the free wall of the right ventricle, and one limb attached to the septal wall. The atrioventricular bundle begins with the union of the nodule of Aschoff-Tawara and a flattened cone-shaped bifurcated trunk (Erhart, 1937).

The subclavian and carotid arteries all arise from a single innominate trunk (Beddard, 1889). There are six vitelline vessels; four are vestigial, one is a large vein running through a mesodermic cord to the mesoduodenum, and the sixth is a small artery that originates in the mesentery behind the vitelline peduncle and inserts in the ileum (Oria, 1937). The vessels found in the renal hilum of the kidneys of four animals varied in number from three to six (Souza et al., 1988). The endodermic allantois is accompanied by three allantoic vessels, and one long vein branching off. A dense capillary rete lies immediately subjacent to the uterine epithelium (Oria, 1937).

The greater height relative to length of the telencephalon in tapirs is unique among ungulates. The rhinencephalon is larger than that in horses and artiodactyls due to the greater development of the olfactory bulbs and the neopallium. Lengths of an adult and a fetal telencephalon, less the olfactory bulbs, were 70 and 31 mm respectively; widths were 70 and 33 mm, and heights were 57 and 25 mm (Friant, 1943).

The neocortex is poorly developed and has a surface area in the left hemisphere of 19.8 mm², and its thickness (mm) is: frontal area, 2.4; temporal area, 2.7; occipital area, 2.1. The brain of a 300 kg individual had a mass of 262 g (Haarmann, 1974), a 160 kg tapir had a 192 g brain, and a 160 kg male had a 169 g brain (Kruska, 1973). Innervation of the shoulder and neck region was described by Donat (1981) and that of the limbs by Campbell (1936, 1945).

The tongue is covered with fungiform papillae except for the medial area. Mayer's organ, with a transverse row of four circumvallate papillae, is situated on the anterior margin of the tongue.

The hard palate has fifteen ridges and one incomplete ridge on each side (Beddard, 1889). The vocal cords are slight but sharp folds thickened anteriorly (Turner, 1850). There is no distinct cartilaginous closing fold of the pharyngeal opening of the eustachian tube inside the lateral mucous membrane and the tube does not have a lumen in the vicinity of the outpocketing of the diverticulum. Each air sac is subdivided into a large caudomedial section, and a small oralateral one, connected with the pharyngeal opening of the eustachian tube (Lechner, 1932). The sac is situated beneath the ear between the stylohyal bone and the base of the sphenoid. The eustachian tube runs as a groove along part of the upper surface of the sac before it opens into the posterior nares (Turner, 1850).

The salivary glands are well developed with the parotid glands meeting ventrally in front of the neck, and surrounding the base of the auricle. The molar glands form a conglomerate mass situated between the buccinator muscle and the mucous lining of the mouth (Turner, 1850).

The esophagus enters the stomach about a third of the way from the left side. The cuticular membrane continues from the esophagus into the stomach for 7.5 cm toward the left end and 17.8 cm toward the pylorus. The rest of the stomach cavity has a smooth or compact villous surface with a few narrow well-defined rugae. The villous coat is thicker and more glandular near the pylorus (Owen, 1830).

The small intestine of one Brazilian tapir measured 8.2 m in length (Beddard, 1889) and that of another young individual was 11 m (Turner, 1850). Valvulae conniventes coat the small intestine for 10 to 12.5 cm, whereas the remainder is smooth (Owen, 1830). Most of the mesenteric gland mass lies at the end of the ileum. The small intestine is attached to the cecum by a large fold extending along the small intestine for about 30 cm. The circular muscle layer of the small intestine has fibrous connective tissue, whereas that of the mucosa is adenoidal (Schiller, 1915). The cecum is sacculated by four equally spaced fibrous bands (Beddard, 1889) and was 37.5 cm in length in one tapir (Owen, 1830). *T. terrestris* absorbs a larger proportion of dietary calcium than do ruminants (Schryver et al., 1983).

The proximal end of the colon is enlarged and bound to the cecum by fibrous bands (Beddard, 1889). The large intestine begins in transverse folds and becomes a loose mesocolon where the feces begins to be produced. The length of the large intestine of one individual was 270 cm (Owen, 1830).

The gall bladder duct emerges from a transverse band and terminates in the duodenum 7.5 cm from the pylorus. The pancreas extends from the spleen to the duodenum and is 22.5 cm long (Owen, 1830). A biliary orifice is about 5 cm from the pylorus; the pancreatic opening is situated opposite the orifice and about 2.5 cm from the pylorus (Beddard, 1889). The liver has four lobes and occupies the epigastric region. The two external lobes are connected by a ventral transverse band. The third lobe from the right is the largest and has two deep notches. The coronary ligament and remains of the umbilical cord pass through the left notch (Owen, 1830). There are well-developed Spigelian and caudate lobes (Beddard, 1889).

The kidneys are conglobate, measuring 15 by 8.8 cm. The cortex is 2.5-3 cm wide and the suprarenal capsules are 7.5 by 2.5 cm. The testes are elongate and about 10 cm long and are situated in the scrotum about 15 cm from the anus. The cremaster is composed of a fasciculus of fibers up to 2.5 cm wide (Owen, 1830). The urinary bladder is about 20 by 15 cm with walls 3 mm thick. The bulbourethral gland is 6 by 2 cm. The penis measures 49 cm from the bulbourethral gland to the tip of the glans. The microscopic and gross anatomy of the rest of the male urogenital system was described by Hofmann (1923). In tapirs generally, urine can be sprayed backward 1 m by females and to 5 m by males (Kuehn, 1986).

During the second through the sixth months of gestation, there is an epitheliochorial placenta. The uterus is bicornuate (Schauder, 1944) and the mucosa of a fertile horn has active tubular glands (Oria, 1937). The remainder of the female reproductive system, especially that of the gravid uterus and placenta at various stages of gestation, was described by Schauder (1928, 1944). The vitelline sac is relatively large but not proportionately active with a poorly developed epithelium and obliterated vitelline duct. The endodermic allantois has a more developed and active epithelium and joins the chorion to form the allanto-chorion. The amniotic sac is covered by the vitelline and allantoic tissues, which occupy most of the exocoelom (Oria, 1937).

The proboscis of *T. terrestris* is a highly flexible tactile organ with sensory vibrissae (Fradrich and Thenius, 1972). The foot posture is plantigrade. Digits are well separated from one another by deep cutaneous interdigital grooves. The nail is black, thick, and solidly attached to the tissue beneath, and is composed of up to 50 hard and dense keratinized laminae. There is a triangular elastic cushion under the first and second phalanges extending from the middle of the digits to the carpals and tarsals. This elastic cushion consists of adipose tissue surrounded by cavities and lacunae. The fibers become denser in the upper surface where they continue as a strap-like ligamentous apparatus over the rest of the digits. Under each third phalanx, posterior to the nail, is a small flat cushion behind the nail, continuous with the main cushion (Bressou, 1950).

ONTOGENY AND REPRODUCTION. Estrus lasts for 2 days and occurs every 50 to 80 days (Fradrich and Thenius, 1972). The earliest ages at which conception occurred were approximately 23 months in a zoo-bred female (Tapir Research Institute, 1971), and an estimated 27 months for another captive (Schurer, 1975). The oldest Brazilian tapir to give birth was 28 years old (Buschelberger, 1987). Gestation periods range from 335 to 439 days (Mallinson, 1974; von Richter, 1966; Tapir Research Institute, 1971).

Pregnancy can be accurately detected in tapirs at 6 or 7 months of gestation by analysis of urinary estrose sulfate level, indexed with creatinine (Kasman et al., 1985). In one instance, the mammae of a captive tapir began to secrete liquid 7 days before birth while the fetus was palpable at the lower right abdomen. A fluid discharge from the vagina began 2 days before birth while the vulva contracted periodically (Tapir Research Institute, 1971). The milk of captive Brazilian tapirs contained total solids of 15.7%. Percentage of protein ranged from 15.7 to 36.3%, carbohydrate from 5.6 to 42%, and fat from 3.4 to 21.7%, depending on the stage of lactation (Kuehn, 1986; Ormrod, 1968).

The birth of two Brazilian tapirs in captivity lasted 3 and 5 min, respectively (Kirschofer, 1963; Schurer, 1975). One young is typical, but twin births do occur (Dittrech, 1969). Parturition, behavior of mother and calf, and reproductive rate of captive tapirs were described by Kirschofer (1963). Breeding records for tapirs in East German zoos were reported by Buschelberger (1987).

Young at birth have a mass of 3.2–5.8 kg (Tapir Research Institute, 1971). The young are dark with patterns of white or yellow stripes and spots (Fig. 1). The sides and back usually have longitudinal stripes extending to the tail whereas the head has spots and irregular stripes. The legs and lower parts of the body have large spots of unequal size and various stripes (Mallinson, 1969; Schurer, 1975). The change from juvenile to adult coloration is sufficiently consistent to allow aging of wild-captured young Brazilian tapirs (Mallinson, 1969).

Young tapirs mouth solid food after the first few days or weeks, but continue to feed primarily on milk as long as it is available. Solid food does not become a major part of the diet until several weeks of age or longer (Tapir Research Institute, 1971; Wilson and Wilson, 1973). One Brazilian tapir calf was weaned at 10 months, although the mother would have continued to nurse (Young, 1961). Longevity in captivity is at least 35 years (Nowak and Paradiso, 1983).

Mass of a captive-born female doubled the first week and tripled by the 15th day (Mallinson, 1969) and another hand-reared calf gained an average of 2.27 kg/week (Wilson and Wilson, 1973). There was no change in the ratio of height to girth (0.658) between the ages of 61 and 605 days in two tapirs, and the ratio of height to length changed only from 0.563 to 0.564. In one female born in captivity, the I1s erupted at 7 days, the I1s at 9 days, the C1s at 23 days, and premolars at 25 days. A captive male started shedding deciduous teeth at 20 months; by 25 months, all permanent incisors were present, and all canines were replaced at 29 months (Tapir Research Institute, 1971). The deciduous P4/p4 function simultaneously with the permanent teeth until after the m2 erupts, which may occur as late as 13 months of age. Occlusion of the M3/m3 does not occur until other permanent teeth are well worn (Simpson, 1945). *T. terrestris* reaches its definitive adult size in terms of skull length by the time M2 has erupted (Hershkovitz, 1954), with all growth usually completed by about 18 months of age (Young, 1961).

ECOLOGY. The Brazilian tapir usually is found in mesic, transitional, and humid forests, near rivers. The typical habitat of *T. terrestris* includes areas with annual rainfall between 2,000 to

4,000 mm, an average temperature of 27.4°C, and relative humidity around 75% (Sturm et al., 1970). The Brazilian tapir is unique among terrestrial mammals in that its distribution (Grimwood, 1969) and diet (Bodmer, 1990b) are not affected by seasonal inundation. Although species of Neotropical tapirs are usually allopatric, *T. t. colombianus* and *T. bairdii* do occur sympatrically in northwestern Colombia in the valley of the upper Rio Sinu and east of the Gulf of Uraba (Haffer, 1970; Hershkovitz, 1954).

These animals move between forests and thickets in the day, but at night feed in grassy or scrubland areas, marshes, lakes, and streams (Hershkovitz, 1954). These daily migrations result in well-worn paths (Husson, 1978) used by natives (Tate, 1939); such trails are sometimes used for hunting tapirs (Cabrera and Yepes, 1940). Brazilian tapirs frequent rivers where they find refuge from predators and ectoparasites (Hershkovitz, 1954; Miller, 1930); mud baths also are utilized (Husson, 1978). They have, however, been reported from the Descalvados region of Brazil in relatively dry areas (Miller, 1930). They have been observed moving to areas of lower elevation during periods of heavy rain (Cabrera and Yepes, 1940).

The major predators of *T. terrestris*, other than man, are jaguars, *Felis onca*, (Cabrera and Yepes, 1940; Hershkovitz, 1954; de Magalhaes, 1938) and crocodylians (Husson, 1978). This tapir is host to a variety of internal parasites including the ciliates *Buissonella tapiri*, *Balantidium coli*, and *Blepharocorys cardionucleata* (Wolska and Piechaczek, 1970), *Prototapirella intestinalis* found in the cecum (da Cunha, 1918), *Buissonella tapiri* in the cecum and colon (da Cunha and Muniz, 1925), and *Bundlea batypharyngea* in the cecum (da Cunha and Muniz, 1928). Nematodes include *Neomurshidia monostichia* (Chabaud, 1957) and *Teseraia* (Chabaud and Bain, 1981), *Physocephalus nitidulans* in the stomach (Cuocolo, 1942), and *Probstmayria tapiri*, a new species found in *T. t. terrestris* in French Guiana (van Waerebeke et al., 1988). A probable case of schistosomiasis has been reported (Yamini and van Veen, 1988). Mites reported for *T. terrestris* include *Sarcoptes tapiri* (Kutzer and Grunberg, 1967), which causes sarcoptic mange. Ticks include *Ornithodoros (alectorubius) tuttlei* (Jones and Clifford, 1972), *Amblyomma ovale* (Guglielmone and Mangold, 1986), and *Haemophysalis juxtakochi* (Guglielmone et al., 1992).

Captive and wild Brazilian tapirs have developed coccidiosis (Dillehay et al., 1985), actinomycete infection (Alexander, 1978), and rabies (Nilsson et al., 1968). Various strains of tuberculosis have been isolated in the Brazilian tapir (Chevalier et al., 1969; Urbain et al., 1943). Oncocytes in the glandulae palatinae have been reported (Rother et al., 1972). Death in Brazilian tapirs resulted from cardiac failure (Tapir Research Institute, 1971) and cholelithiasis (Starzynski, 1965). Frolika (1986) reported causes of death in captive *T. terrestris*.

Tapirs are generalized browsers and grazers, with the bulk of the diet usually being green shoots of common browse plants. Other foods include fruits, leaves, stems (Hershkovitz, 1954), fresh sprouts, small branches, grasses, aquatic plants (Fradrich and Thenius, 1972), the bark of trees (de Magalhaes, 1938), and aquatic organisms (Hershkovitz, 1954), possibly including fish (Husson, 1978). Tapirs also visit plantations for cane, melons, cocoa, (Fradrich and Thenius, 1972), rice, and corn (de Magalhaes, 1938), and they seek salt accumulations (Cabrera and Yepes, 1940; de Magalhaes, 1938).

Hunters in Mato Grosso, Brazil, know the seasonal dietary preferences of the Brazilian tapir and wait, at night, by stands of fruiting plants including: *Spondias lutea*, *Mauritia*, *Eudoplestra uchi*, *Jessenia*, *Anacardium giganteum*, *Parinari sprucei*, *Genipa americana*, *Maximilliana*, and *Pouteria* (Ayres and Ayres, 1979). In Surinam, *Mauritia flexuosa*, *Lonchocarpus*, and *Spondias* leaves and fruit are common foods (Husson, 1978). In northeastern Peru, *M. flexuosa* drupes were the dominant fruit item in a diet that was one-third fruit; this is a relatively high rate for a large nonruminant ungulate, but the fruit is highly nutritious and occurs in large patches (Bodmer, 1990a). Resource partitioning between the Brazilian tapir and two species each of peccary (*Tayassu tajacu*, *T. pecari*) and brocket deer (*Mazama americana*, *M. gouazoubira*) is achieved mainly through differences in digestive morphology and the tapir's use of almost equal percentages of fruit, leaf, and fiber (Bodmer, 1991).

The first introduction of a Brazilian tapir to a European zoo may have taken place in 1704 (Kourist, 1973). Captive tapirs should be vaccinated against tetanus, and eastern, western, and Venezuelan equine encephalomyelitis, if these diseases occur in the area (Kuehn, 1986), and tested routinely for tuberculosis (Mann et al., 1981).

Immobilizing drugs used for *T. terrestris* include Xylazine (Rom-pun—Rapley and Mehren, 1975) and etorphine (Kuehn, 1986); the sedative, Diazepam (Kutschmann et al., 1986), and the anesthetic tiletamine-Zolazepam (Hughes et al., 1986) also have been used. Doproam has been used to arouse a tranquilized animal (Rapley and Mehren, 1975); diprenorphine may be used to counteract etorphine (Kuehn, 1986). Management of captive tapirs has been described by Horan (1983).

Tapirus terrestris is domesticated easily (de Magalhaes, 1938; Fradrich and Thenius, 1972), and has been taught to pull plows and to allow riding by children. This species is widely used by native people for meat and the hide, which is used as leather for reins and whips (Fradrich and Thenius, 1972). Nine Brazilian tapirs with a total mass of 990 kg made up 11.8% of the total meat taken by four hunters, feeding 638 people during a period of 4 months (Ayres and Ayres, 1979). In the Rio Blanco and Upper Rio Tahuayo region of Peru, fourteen animals represented 5% of the total harvest of ungulates in one year (Bodmer et al., 1988). Hunters usually work with dogs (Fradrich and Thenius, 1972; Tate, 1939) and sometimes use poison arrows (Fradrich and Thenius, 1972). To the Bororo Indians of Brazil, the Brazilian tapir is a taboo animal or "Santo," which they never kill. They are reported, however, to lasso tapirs, tie them to trees, and await the arrival of other natives, without such taboos, to kill them (Miller, 1930).

In the Matto Grosso of Brazil, the hides of tapirs are used (Miller, 1930), whereas Peruvian tapirs are considered game animals hunted for food, but rarely for the hides (Grimwood, 1969). Professional pelt hunters, however, took enough Brazilian tapirs and other ungulates in Peru that such hunting was prohibited there in 1973 (Bodmer et al., 1988).

Tapirs are ecologically important components of tropical communities. Brazilian tapirs accounted for 25% (380 kg/km²) of the total biomass of sixty-four species of fauna on a ranch in the Brazilian pantanal (Schaller, 1983). Once common throughout its range, the Brazilian tapir has become increasingly rare, especially in Argentina (Olog, 1977). The decline has been attributed to a variety of factors including a long gestation period, a single young, intensive hunting pressure, and deforestation (Husson, 1978). The need for conservation and better management was noted as early as the 1930s in Brazil (de Magalhaes, 1938). Consequently, *Tapirus terrestris* is now listed as endangered by the U.S. Fish and Wildlife Service and is on Appendix II of the Convention on International Trade in Endangered Species.

BEHAVIOR. Primarily adapted to forest habitats, tapirs have poor eyesight but good olfactory senses (Fradrich and Thenius, 1972; Husson, 1978; Miller, 1930). They engage in vocal communication but have little social interactions (Hunsaker and Hahn, 1969). *Tapirus terrestris* is found in groups only during the mating season. The Brazilian tapir is largely a nocturnal animal and is commonly observed during full moon (Cabrera and Yepes, 1940; Husson, 1978).

Periods of deep sleep occurred at 2200–2300 h and again at 0100–0200 h, interspersed with periods of eating, defecating, and general activity (von Richter, 1966). In the wild, tapirs are active at all times except during the hottest period of the day (Fradrich and Thenius, 1972; de Magalhaes, 1938). A group of captive animals exhibited typical ungulate behavior showing periods of feeding (15.5%), moving, foraging (8.6%), walking (13.4%), and social behavior, interspersed with resting (sleeping 47.9%) throughout the day. Nursing juvenile and pregnant females spent more time sleeping and less time eating, which suggests age and sexual variation in the activity budget and in space use by captive Brazilian tapirs (Mahler, 1984).

Although usually shy and retiring (de Magalhaes, 1938), tapirs can act violently at times, especially during sexual excitation and intrusion of territories (Tapir Research Institute, 1971), and if cornered, will charge (Cabrera and Yepes, 1940). When alarmed, they blindly crash into the brush or dive into the nearest body of water (de Magalhaes, 1938; Miller, 1930). Such behavior may remove leeches and deter large predators such as jaguars, which jump onto the tapir's shoulders (Cabrera and Yepes, 1940; de Magalhaes, 1938). When defending young, adult Brazilian tapirs repel jaguars and hunting dogs by kicking them (Husson, 1978). Captive female tapirs are said to be more gentle than males (Tapir Research Institute, 1971).

In a slow walk, a tapir keeps its head lowered, whereas in a trot, the head is lifted. Tapirs also can gallop, climb inclines well, and are excellent swimmers (Fradrich and Thenius, 1972; Hersh-

kovitz, 1954). They jump vertical fences by rising on their hind legs and leaping. In lying down, they sit first (Fradrich and Thenius, 1972). Defecation occurs in and out of the water, but in captivity some tapirs do not defecate regularly unless they are allowed to bathe (Kuehn, 1986).

Four vocalizations used by Brazilian tapirs in social interactions include two shrill calls produced by the vocal cords during fear, pain, appeasement, and exploration; a clicking noise produced by tongue and palate, possibly used as a method of species identification; and a nasal snort produced by forcing air through the snout, which is associated with aggression. Most of the sounds are of low intensity, whereas those of high intensity are used mostly in pain, fear, and in warning other members of a group. Mates attract each other by low intensity squealing and clicking calls rather than through display (Hunsaker and Hahn, 1969). Venezuelan native tribesmen attract Brazilian tapirs by imitating these vocalizations (Tate, 1931). This tapir also produces a puffing noise when disturbed by insects (Husson, 1978).

Tapirs also engage in non-vocal means of communication. Males urinate regularly on the same spot, sniffing the area first, then turning and urinating on it with the penis arched backwards, pawing the ground both before and after urinations (Kuehn, 1986). In addition to urine marking, the Brazilian tapir may possess two facial glands used in marking (Sontag, 1974). Flehmen is performed after sniffing or licking the urine of a conspecific. When two tapirs meet, their ears go forward but when enraged, the ears lay back (Fradrich and Thenius, 1972).

Males and females do not remain together for an extended period of time (Cabrera and Yepes, 1940; Miller, 1930). During courtship in captivity, males follow females nose-to-tail and give females close attention, sucking on their ears and playing; copulation is preceded by periods of excitability, carousel movements, flehmen chasing, and high pitched whistling (Tapir Research Institute, 1971; Mallinson, 1974). Copulation takes place in or out of water (Tapir Research Institute, 1971). A captive female, prior to parturition, was observed behaving restlessly before it assumed a perching position, and gave birth (Fradrich and Thenius, 1972). Some females give birth while lying on their sides (Kirschofer, 1963).

Calves may initiate suckling by pushing the mother and both may be prone during the period of suckling (Fradrich and Thenius, 1972). While some ungulates are "hidiers," that is, the young initially remain hidden and at a distance from the mothers, young Brazilian tapirs are "followers," maintaining close proximity to the mother. Studies of captive animals suggest that in contrast to "hidiers," mother–young associations in "followers" decrease over time during the first seven weeks (Ralls et al., 1987).

GENETICS. *Tapirus terrestris* has a diploid chromosome number (2n) of 80. The autosomes consist of two submetacentrics and seventy-six acrocentrics, the X-chromosome is submetacentric, and the Y is acrocentric (Hsu and Benirschke, 1975). One zoo reported having a *T. terrestris* × *T. bairdii* hybrid (Tapir Research Institute, 1971). Albino Brazilian tapirs have been born at two zoos (Lindber, 1984; Smielowski, 1979).

REMARKS. The word "tapir" comes from the Brazilian Tupi language while the common name "danta" is a corruption of the Spanish word for elk, "alce" or "anta" (Hershkovitz, 1954). The Bra-Tupi people use the names Tapira-caaivara and Tapira-caapora which means "ox of the bush" (de Magalhaes, 1938). Other local names include gran bestia, Capa huagra, Mborebi, Sacha Vaca, Denta, Kemare (Campa), Pahuaraa (Chayhuaita), Paman (Achual), Tapchire, Tapiyre, Tappirousos (Hershkovitz, 1954), Maikuri (Kamarakoto), Waira (Taurepan and Makuchi), and Maipura or Maipuri (Kalina) (Simpson, 1941).

We thank S. Johnson for assistance in locating literature, M. Hegyi for translation of some foreign articles, L. Figueroa and G. Sarro for typing, L. A. Ruedas and A. Boyd for help with figures, and G. Musser, American Museum of Natural History, for loan of the skull. In addition, M. Alberico, S. Anderson, P. Hershkovitz, and other reviewers provided helpful comments. The photograph of the tapirs was kindly provided by the New York Zoological Society.

LITERATURE CITED

ALEXANDER, I. D. 1978. Actinomycete infection in a tapir (*Tapirus terrestris* L.). *Journal of Zoo Animal Medicine*, 9:124–126.

- AMEGHINO, F. 1909. Una nueva especie de tapir (*Tapirus spezzinii*). Anales Museo Nacional de Buenos Aires, 20:31-38.
- . 1911. L'avant-premiere dentition dans le tapir. Anales Museo Nacional de Buenos Aires, ser. 3, 13:1-30.
- AYRES, J. M., AND C. AYRES. 1979. Aspectos da caca no alto Rio Aripuana. Acta Amazonica, 9:287-298.
- BEDDARD, F. E. 1889. Notes upon the anatomy of the American tapir (*Tapirus terrestris* L.). Proceedings of the Zoological Society of London, 1889:252-258.
- BLUMENBACH, J. F. 1779. Handbuch der Naturgeschichte. Göttingen, Johann Christian Dieterich, 559 pp.
- BODMER, R. E. 1990a. Fruit patch size and frugivory in the lowland tapir, *Tapirus terrestris*. Journal of Zoology (London), 222:121-128.
- . 1990b. Responses of ungulates to seasonal inundations in the Amazon floodplain. Journal of Tropical Ecology, 6:191-210.
- . 1991. Influence of digestive morphology on resource partitioning in Amazonian ungulates. Oecologia, 85:361-365.
- BODMER, R. E., T. G. FANG, AND L. M. IBANEZ. 1988. Ungulate management and conservation in the Peruvian Amazon. Biological Conservation, 45:303-310.
- BRESSOU, C. 1950. Le pied des tapirides. Mammalia, 14:140-144.
- BUSCHELBERGER, P. 1987. Mitteilung zur Lebenserwartung und Fortpflanzung von *Tapirus terrestris*. Zoologische Garten, 57:371-372.
- CABRERA, A. 1961. Catalogo de los mamíferos de America del Sur. Revista del Museo Argentino de Ciencias Naturales. Ciencias Zoológicas, 4(2):309-732.
- CABRERA, A., AND J. YEPES. 1940. Mamíferos Sud-Americanos. Compania Argentina de Editores, Buenos Aires, 370 pp.
- CAMPBELL, B. 1936. The comparative myology of the forelimb of the hippopotamus, pig, and tapir. American Journal of Anatomy, 59:201-247.
- . 1945. The hindfoot musculature of some basic ungulates. Journal of Mammalogy, 26:421-424.
- CHABAUD, A. G. 1957. Revue critique des nematodes du genre Quilonia et du genre Murshidia. Annales de Parasitologie Humaine et Comparee, 32:98-131.
- CHABAUD, A. G., AND O. BAIN. 1981. Description of *Spirobakerus weitzeli* new genus new species and remarks on spirocercid nematodes. Annales de Parasitologie Humaine et Comparee, 56:73-80.
- CHEVALIER, H. J., K. H. BOHM, AND J. SEEGER. 1969. Humane tuberkulose beim tapir. Kleintierpraxis, 14:213-215.
- CUOCOLO, R. 1942. Reacao fibrosa da parede do estomago de *Tapirus americanus* provocada por *Physocephalus nitidulus* (Schneider 1860). Arquivos do Instituto Biologico Sao Paulo, 13:271-282.
- DA CUNHA, M. 1918. Sobre os ciliados intestinaes dos mamíferos. Brasil-Medico, 32:161.
- DA CUNHA, M., AND J. MUNIZ. 1925. Contribution to the knowledge of ciliata parasitic in Mammalia of Brazil. Scientia Medica, 3:740-747.
- . 1928. Nouveau cilie parasite caecum du *Tapirus americanus*. Description d'un nouveau genre. Comptes Rendus des Seances. Societe de Biologie (Paris), 98:631-632.
- DE MAGALHAES, A. C. 1938. Anta, Tapir. Boletim Biologico, 3:175-178.
- DILLEHAY, D. L., T. R. BOOSINGER, AND S. MACKENZIE. 1985. Coccidioidomycosis in a tapir. Journal of the American Veterinary Medical Association, 187:1233-1234.
- DITTRICH, L. 1969. Zwilling beim flachland tapir, *Tapirus terrestris* (Linne, 1758). Säugetierkundliche Mitteilungen, 17:367.
- DONAT, K. 1980. The auricular muscles of the *Tapirus terrestris*. Anatomia, Histologia, Embryologia, 8:284-286.
- . 1981. The musculus cullaris in the American tapir *Tapirus terrestris*. Anatomia, Histologia, Embryologia, 10:125-129.
- EARLE, C. 1889. Some points in the comparative osteology of the tapir. Science, 21:118.
- ERHART, M. B. 1937. Feixe atrio-ventricular de his no *Tapirus americanus*. Arquivo de Anatomia e Antropologia, 18:37-42.
- ERXLEBEN, J. C. P. 1777. Systema regni animalis per classes, ordines, genera, species, varietates, cum synonymia et historia animalium. Classis I. Mammalia. Weygandianis, Lipsiae, 636 pp.
- EVARESTOVA, A. 1946. Gemogramma Tapira. Proceedings of the Moscow Zoological Park, 3:219-220.
- FISCHER, G. 1814. Zoognosia tabulis synopticis illustrata. Nicolai Sergeidis Vsevolozsky, Moscow, 3:1-734.
- FRACKOWIAC, H., AND S. GODYNICKI. 1992. Head arteries in lowland tapir (*Tapirus terrestris*). Roczniki Akademii Rolniczej w Poznaniu, 229:15-20.
- FRADRICH, H., AND E. THENIUS. 1972. Tapirs. Pp. 17-33, in Animal Life Encyclopedia, Vol. 13 (B. Grzimek, ed.). Van Nostrand Reinhold, New York, 566 pp.
- FRIANT, M. 1943. Le telencephale des tapirides. Anatomischer Anzeiger, 94:26-41.
- FROLIKA, J. 1986. Erkrankungen beim im zoo gehaltenen scharbrackentapir (*Tapirus indicus*) und flachlandtapir (*Tapirus terrestris*). Erkrankungen Zootiere, 28:189-193.
- GAMBARYAN, D. P. 1964. Morfofunktionalny analiz myshts konechnustei tapira (*Tapirus americanus*). Zoologische Jahrbuch Akademie Naukowe Arm. Eshr., 13:5-50.
- GMELIN, J. F. 1788. Systema naturae per regna tria naturae, secundum classes, ordines, genera, species, cum characteribus, differentiis, synonymis, locis. Vol. I. Regnum Animale. Class 1, Mammalia. Thirteenth ed. (revised by J. F. Gmelin). G. E. Beir, Lipsiae, 232 pp.
- GRAY, J. E. 1867. Notice of a new species of American tapir, with observations on the skulls of *Tapirus*, *Rhinochoerus*, and *Elasmognathus* in the collection of the British Museum. Proceedings of the Zoological Society of London, 1867:876-886.
- . 1872. Notes on a new species of tapir from the snowy regions of the Cordilleras of Ecuador and on the young spotted tapirs of North America. Proceedings of the Zoological Society of London, 1872:483-492.
- GRIMWOOD, I. R. 1969. Notes on the distribution and status of some Peruvian mammals 1968. Special Publications of the American Committee for International Wildlife Protection, New York Zoological Society, 21:1-86.
- GUGLIEMONE, A. A., AND A. J. MANGOLD. 1986. Hallazgo de *Amblyomma ovale* Koch 1844 (*Amblyomma fozsum* Neumann 1892) en las provincias de Salta y Jujuy, Argentina. Veterinaria Argentina, 3:167-168.
- GUGLIEMONE, A. A., C. R. AUFRANC, AND A. J. MANGOLD. 1992. *Haemophysalis juxtakochi* (Ixodidae) in relation to the phytogeography of Argentina. Annales de Parasitologie Humaine et Comparee, 67:91-93.
- HAARMANN, K. 1974. Morphological and histological investigations on the neocortex of several Perissodactyla. Acta Anatomica, 90:285-299.
- HAFFER, J. 1970. Geologic-climatic history and zoogeographic significance of the Uraba region in northwestern Colombia. Caldasia, 10:603-636.
- HATCHER, J. B. 1896. Recent and fossil tapirs. American Journal of Science, Ser. 4, 1:161-180.
- HERMANN, R. 1924. Ein neuer tapir aus Brasilien und ost Bolivien. Mitteilungen aus dem Zoologischen Museum in Berlin, 11:167-168.
- HERSHKOVITZ, P. 1954. Mammals of northern Colombia. Preliminary report no. 7 tapirs (genus *Tapirus*), with a systematic review of American species. Proceedings of the United States National Museum, 103:465-496.
- HOFMANN, L. 1923. Zur anatomie des männlichen elefanten-tapir- und hippopotamus-genitale. Zoologische Jahrbucher Abteilung für Anatomie und Ontogenie der Tiere, 45:161-212.
- HOOIJER, D. A. 1961. Dental anomaly in *Tapirus terrestris* (L.). Bijdragen tot de Dierkunde., 31:63-64.
- HORAN, A. 1983. An outline of tapir management. Proceedings of the Symposium on the Association of British Wild Animal Keepers, 7:24-29.
- Hsu, T. C., AND K. BENIRSCHKE. 1975. An atlas of mammalian chromosomes. Vol. 9, Folio 436. Springer-Verlag, New York, unpagued.
- HUGHES, F., M. LECLERC-CASSAN, AND J. P. MARC. 1986. Anesthésie des animaux non domestiques. Essai d'uo nouvel anesthésique: l'association tiletamine-Zolazepam (Zoetil N.D.). Recueil de Medecine Veterinaire de l'Ecole d'Alfort, 162:427-431.

- HUNSAKER, D., II, AND T. C. HAHN. 1969. Vocalization of the South American tapir (*Tapirus terrestris*). *Animal Behaviour*, 13:69-74.
- HUSSON, A. M. 1978. The mammals of Suriname. *Zoologische Monographien, Rijksmuseum van Natuurlijke Historie*, 2:1-569.
- JONES, E. K., AND C. M. CLIFFORD. 1972. The systematics of the subfamily Ornithodorinae (Acarina: Argasidae). A revised key to larval Argasidae of the western hemisphere and description of seven new species of *Ornithodoros*. *Annals of the Entomological Society of America*, 63:730-740.
- KASMAN, L. H., B. MCCOWAN, AND B. L. LASLEY. 1985. Pregnancy detection in tapirs by direct urinary estrous sulfate analysis. *Zoo Biology*, 4:301-306.
- KATHARINER, F. L. 1914. Das fubskelett des tapirs. *Naturwissenschaftliche Wochenschrift Jena*, 13:422-423.
- KIRSHSHOFER, R. 1963. Das Verhalten der giraffengazelle, elenantilope und des flachland tapirs bei der geburt: einige Bemerkungen zur vermehrungsrate und generationsfolge dieser arten im Frankfurter Zoo. *Zeitschrift fur Tierpsychologie*, 20:143-159.
- KLADETZKY, J. 1956. Atlas und epistropheus vom tapir (erganzung zum Beitrag: zur entwicklung des dens epistropheis). *Gegenbaurs Morphologisches Jahrbuch*, 97:193-201.
- KLAITS, B. G. 1972. The moving mesaxonian manus: a comparison of tapirs and rhinoceroses. *Mammalia*, 36:126-145.
- KOENIGSWALD, R. V. 1930. Die tapirreste aus dem aquitan von ulm und mainz. *Palaeontographica Stuttgart*, 73:1-29.
- KOURIST, W. 1973. Fruhe haltung von grossaugetiehn teilh (Schloss) die ersten zweihornngen nashorner, die tapire und wale in den zoologischen garten und anderen tiersammlungen. *Zoologische Beitrage*, 19:137-150.
- KRUSKA, D. 1973. Cerebralization evolution of the brain and changes in brain size as a cause of domestication within the order Perissodactyla and a comparison with the order Artiodactyla. *Zeitschrift fur Zoologische Systematik und Evolutionsforschung*, 11:81-103.
- KUEHN, G. 1986. Tapiridae. Pp. 759-763, in *Zoo and wild animal medicine* (M. E. Fowler, ed.). W. B. Saunders, London, 1126 pp.
- KUTSCHMANN, K., G. ALBRECHT, AND M. NEWMANN. 1986. Zur anwendung von Diazepam beim zootier. *Erkrankungen Zootier*, 28:105-108.
- KUTZER, E., AND W. GRUNBERG. 1967. *Sarcoptes raude* (*Sarcoptes tapiri* nov. spec.) bei tapir en (*Tapirus terrestris*). *Zeitschrift fur Parasitenkunde*, 29:46-60.
- LECHNER, W. 1932. Ueber die tubendivertikel (luftsacke) beim tapir. Ein beitrae zur anatomie des tapirs (*Tapirus americanus* Linne). *Anatomischer Anzeiger*, 74:250-265.
- LIAIS. 1872. *Climats, geologie, faune et geographie botanique du Bresil*, p. 397 (not seen, cited in Hershkovitz, 1954).
- LINDBER, A. 1984. Ein albinotischer flachland tapir (*Tapirus terrestris*) in Kolmardens Djurpark. *Zoologische Garten*, 54:357-359.
- LINNAEUS, C. 1758. *Systema naturae per regna tria naturae, secundum classes, ordines, genera, species, cum characteribus, differentiis, synonymis, locis*. Tenth ed. Laurentii Salvii, Stockholm, 1:1-824.
- MAHLER, A. E. 1984. Activity budgets and use of exhibit space by South American Tapir (*Tapirus terrestris*) in a zoological park setting. *Zoo Biology*, 3:35-46.
- MALLINSON, J. J. C. 1969. Reproduction and development of Brazilian tapir, *Tapirus terrestris*. *Annual Report of the Jersey Wildlife Preservation Trust*, 6:47-52.
- . 1974. Establishing mammal gestation periods at the Jersey Zoological Park. *International Zoo Yearbook*, 14:184-187.
- MANN, P. C., M. BUSH, D. C. JANSSEN, E. S. FRANK, AND R. J. MONTALI. 1981. Clinicopathologic correlations of tuberculosis in large zoo mammals. *Journal of the American Veterinary Medical Association*, 179:1123-1129.
- MAZUR, G., AND C. BRAUNITZER. 1984. Perissodactyla: die primarstruktur der hamoglobine eines flachlandtapirs (*Tapirus terrestris*): Glutaminsaure in position 2 der B-Ketten. *Hoppe-Seyler's Zeitschrift fur Physiologische Chemie*, 365:1097-1106.
- MERRIAM, C. H. 1895. Brisson's genera of mammals, 1762. *Science, new series*, 1:374-377.
- MILLER, F. W. 1930. Notes on some mammals of southern Mato Grosso, Brazil. *Journal of Mammalogy*, 11:10-22.
- MOREIRA, L. E. 1973. Mamíferos fósseis em Jaupaci. *Goias Estudos Leopoldenses*, 26:49-52.
- NILSSON, R., R. MOACYR, W. SUCAY, AND O. L. PASQUALIN. 1968. Diagnosticoda Raiva. Observacoes sobre o tempo de incubacao e a duracao da doenca em Camundongos no periodo de 1960 a 1966. *Arquivos do Instituto Biologico*, 35:1-7.
- NOWAK, R. M., AND J. L. PARADISO. 1983. *Walker's mammals of the world*. Fourth ed. The Johns Hopkins University Press, Baltimore, 2:569-1362.
- OLROG, C. C. 1977. La situacion presente de los carnivoros y ungulados Argentinos. *Reunion Iberoamericana de Zoologia Vertebrada*, 1:619-623.
- ORIA, J. 1937. Estudo embriologico do *Tapirus americanus*. 1: Nota previa: Annexos embriyonarios e typo de placentacao. *Anais da Academia Brasileira de Ciencias*, 9:263-267.
- ORMROD, S. 1968. Milk analysis of the South American tapir, *Tapirus terrestris*. *International Zoo Yearbook*, 7:157-158.
- OWEN, R. 1830. On the anatomy of the American tapir (*Tapirus americanus* Gmel.). *Proceedings of the Zoological Society of London*, 1830:161-164.
- PAULA COUTO, C. DE. 1980. Fossil mammals of the Pleistocene of Jacupiranga State of Sao Paulo Brazil. *Anais da Academia Brasileira de Ciencias*, 52:135-142.
- RALLS, K., B. LUNDRIGEN, AND K. KRANZ. 1987. Mother-young relationships in captive ungulates: behavioral changes over time. *Ethology*, 75(1):1-14.
- RAPLEY, W. A., AND K. G. MEHREN. 1975. The clinical usage of Rompun (Xylazine) in captive ungulates at the metropolitan Toronto Zoo. *American Association of Zoo Veterinarians Annual Proceedings*, 1975:16-42.
- RAY, C. E., AND A. E. SANDERS. 1984. Pleistocene tapirs in the eastern United States. *Carnegie Museum of Natural History Special Publications*, 8:283-315.
- ROMER, A. S. 1966. *Vertebrate paleontology*. Third ed. University of Chicago Press, 468 pp.
- ROTHER, VON P., H. KRONBERGER, D. WENDLER, AND R. COLE. 1972. Uber das vorkommen von onkozyten bei saugetieren. *Anatomischer Anzeiger*, 132:300-302.
- ROULIN, X. 1829. Memoir pour servir a l'histoire du tapir; et description d'une espece nouvelle appartenant aux hautes regions de la Cordillere des Andes. *Annales des Sciences Naturelle Zoologie Paris*, 17:26-55.
- SCHALLER, G. B. 1983. Mammals and their biomass on a Brazilian ranch. *Arquivos de Zoologia (Sao Paulo)*, 31:1-36.
- SCHAUDER, W. 1928. Uber anatomie, histologie und entwicklung der embryonalanlage des tapirs. *Gegenbaurs Morphologisches Jahrbuch*, 60:106-178.
- . 1944. Der gravide uterus und die placenta des tapirs mit vergleich von uterus und placenta des schweines und pferdes. *Gegenbaurs Morphologisches Jahrbuch*, 89:407-456.
- SCHILLER, A. 1915. Das relief der agmina peyer bei *Tapirus americanus*. *Anatomischer Anzeiger*, 48:54-59.
- SCHINZ, H. R. 1937. Ossifikationsstudien beim neugeborenen schwein und beim neugeborenen tapir. *Mitteilungen der Naturforschenden Gesellschaft in Zurich*, 82:21-44.
- SCHURER, U. 1975. Beobachtungen an einem neugeborenen flachland tapir, *Tapirus terrestris* (L. 1776). *Zoologische Garten*, 46:367-370.
- SCHRYVER, H. F., T. J. FOOSE, J. WILLIAMS, AND H. F. HINTZ. 1983. Calcium excretion in feces of ungulates. *Comparative Biochemistry and Physiology*, 74:375-379.
- SIMPSON, G. G. 1941. Some Carib Indian mammal names. *American Museum Novitates*, No. 1119:1-10.
- . 1945. Notes on Pleistocene and Recent tapirs. *Bulletin of the American Museum of Natural History*, 86:33-82.
- SIMPSON, G. G., AND C. DE PAULA COUTO. 1981. Fossil mammals from the Cenozoic of Acre, Brazil 3. Pleistocene Edentata, Pilosa, Proboscidea, Sirenia, Perissodactyla and Artiodactyla. *Iheringia Serie Geologia*, 6:11-74.
- SMIELOWSKI, J. 1979. Births of white American tapirs. *International Zoo News*, 26:10-15.
- SONTAG, W. A., JR. 1974. Beobachtungen an gemeinsam gehaltenen

- tenen flachlandtapiren (*Tapirus terrestris*) und capybara (*Hydrochoerus hydrochaeris*) in Zürcher Zoo. Zoologische Garten, 44:317-323.
- SOUZA, W. M., M. A. MIGLINO, AND L. J. A. DIDIO. 1988. Topography of blood vessels in the hilum of the kidney in *Tapirus americanus*. Folia Anatomica Universitatis Conimbrigensis (Coimbra), 50:83-88.
- STARZYNSKI, W. 1965. Cholelithiasis in an American tapir (*Tapirus terrestris*). International Zoo Yearbook, 5:195-196.
- STURM, H., A. L. ABOUCHAAR, R. DE BERNAG, AND C. DE HOYOS. 1970. Distribution de animales en las capas bajas de un bosque humedo tropical de la region Carare-Opon (Santander, Colombia). Caldasia, 10:529-578.
- TAPIR RESEARCH INSTITUTE. 1971. Results of a survey of captive tapirs taken by the Tapir Research Institute, between July of 1970 and March of 1971. Tapir Research Institute, Claremont, California: 22 pp.
- TATE, G. H. H. 1931. Random observations on habits of South American mammals. Journal of Mammalogy, 12:248-256.
- . 1939. The mammals of the Guiana region. Bulletin of the American Museum of Natural History, 76:151-229.
- THOMAS, O. 1911. The mammals of the tenth edition of Linnaeus; an attempt to fix the types of the genera and the exact bases and localities of the species. Proceedings of the Zoological Society of London, 1911:120-158.
- TOMES, J. 1851. On the structure of the teeth of the American and Indian tapirs. Proceedings of the Zoological Society of London, 1851:121-124.
- TURNER, H. N. 1850. Contributions to the anatomy of the tapir. Proceedings of the Zoological Society of London, 1850:102-106.
- URBAIN, A., J. NOUVEL, AND U. P. BULLIER. 1943. Tuberculose et osteopathique hypertrophique chez un tapir Americain (*Tapirus terrestris*, L.). Bulletin de Academie Veterinaire de France, 16:132-135.
- VAN WAEREBEKE, D., A. G. CHABAUD, AND G. ANTHONY. 1988. *Probstmayria tapiri*, new species, parasitic nematode of a tapir from the New World. Bulletin du Museum National d'Histoire Naturelle. Section A. Zoologie, Biologie, et Ecologie Animales, 10:3-8.
- VON RICHTER, W. 1966. Untersuchungen über angeborene verhaltensweisen des schabracken tapirs (*Tapirus indicus*) und des flachlandtapirs (*Tapirus terrestris*). Zoologische Beitrage, 12:67-159.
- WEBB, S. D. 1985. Late Cenozoic mammal dispersal between the Americas. Pp. 357-386, in The great American biotic interchange (F. G. Stehli and S. D. Webb, eds.). Plenum Press, New York, 532 pp.
- WILSON, R. A., AND S. WILSON. 1973. Diet of captive tapirs. International Zoo Yearbook, 13:213-217.
- WOLSKA, M., AND H. PIECHACZEK. 1970. Some internal ciliates from American tapir (*Tapirus terrestris*). Acta Protozoologica, 7:221-227.
- YAMINI, B., AND T. W. S. VAN VEEN. 1988. Schistosomiasis and nutritional myopathy in a Brazilian tapir (*Tapirus terrestris*). Journal of Wildlife Diseases, 24:703-707.
- YOUNG, W. A. 1961. Rearing of an American tapir (*Tapirus terrestris*). International Zoo Yearbook, 3:14-15.
- ZIMMERMAN, E. A. W. 1780. Geographische Geschichte der Menschen und der vierfussigen. Thiere, 2:154.

Editors of this account were TROY L. BEST, J. ALDEN LACKEY, and KARL F. KOOPMAN. Managing editor was JOSEPH F. MERRITT.

M. PADILLA, DEPARTMENT OF BIOLOGY, FORDHAM UNIVERSITY, BRONX, NEW YORK 10458; R. C. DOWLER, DEPARTMENT OF BIOLOGY, ANGELO STATE UNIVERSITY, SAN ANGELO, TEXAS 76909.